

# Vet - Light

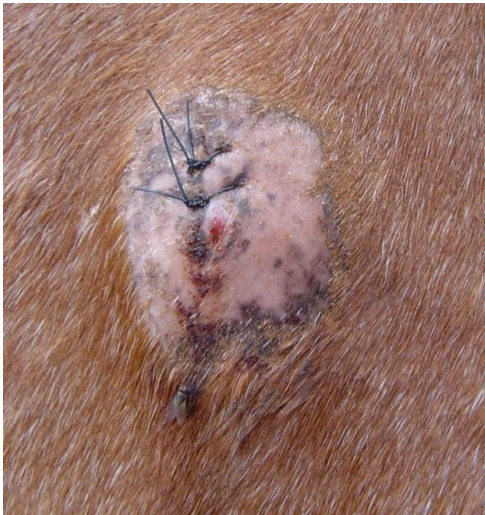

## Case study: Unknown mass

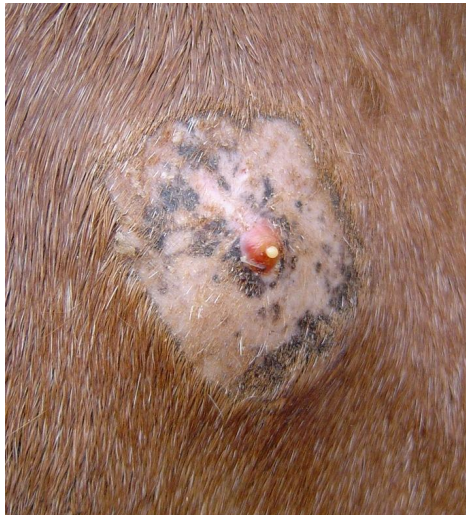**Patient history:** Ginger, a riding school pony, presented with a **chronic, 2 month old, non-healing mass**, 3.5 raised, on her right shoulder area. The mass was opened up by a Vet but no underlying cause could be established. The pony was extremely sensitive and **painful** on and around the area and did not allow people to touch the area.

**Treatment:** Light therapy was used once a day using the **Abscess protocol**.

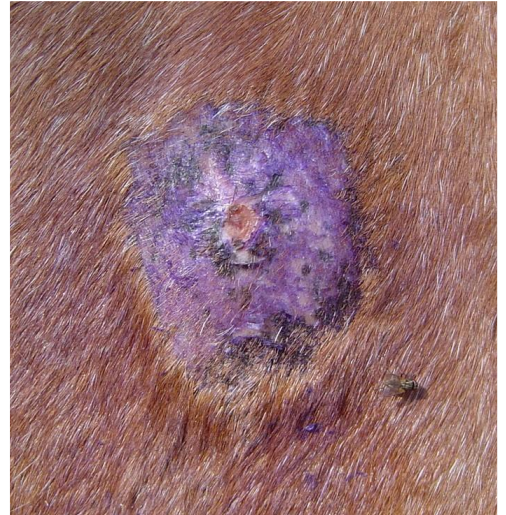
**Outcome:** After just **one treatment the pony was less sensitive** and one could already touch the area. After **5 days the swelling had gone down** completely. The pony made a full recovery.



Presenting mass after draining  
**2 months old**



Note the severe **swelling**



15 days after the start of light therapy  
**Swelling subsided completely**